

# Anatomical variances and dimensions of the superior orbital fissure and foramen ovale in adults

F. Burdan<sup>1, 2</sup>, W. Umławska<sup>3</sup>, W. Dworzański<sup>1</sup>, R. Klepacz<sup>4</sup>, J. Szumiło<sup>4</sup>, E. Starostawska<sup>2</sup>, A. Drop<sup>5</sup>

<sup>1</sup>Department of Human Anatomy, Medical University of Lublin, Lublin, Poland

<sup>2</sup>St. John's Cancer Center, Lublin, Poland

<sup>3</sup>Department of Anthropology, University of Wrocław, Wrocław, Poland

<sup>4</sup>Department of Pathomorphology, Medical University of Lublin, Lublin, Poland

<sup>5</sup>Department of General Radiology and Nuclear Medicine, Medical University of Lublin, Lublin, Poland

[Received 13 June 2011; Accepted 24 August 2011]

*The aim of the study was the retrospective morphological analysis of selected structures of the middle cranial fossa, i.e. foramen ovale and superior orbital fissure, in relation to the external head and cranial diameters in adults from the Lublin region (Poland). The study was performed on data collected during computed tomography examinations of 60 individuals (age 20–30 years), without any cranial or brain abnormalities. Based on the post-processing reconstructions, 3-dimensional views of the skull and head were obtained. The length and width of both structures, as well as thickness of the frontal, temporal, and occipital squamae, were measured. The morphology of the ovale foramina and superior orbital fissures were checked. The length and width of the skull and head were the only parameters that significantly differed between males and females. The thickness of the frontal and temporal squama was insignificantly lower in males than in females. Almond and oval shapes were the most typical for the foramen ovale. The superior orbital fissure was found as a wide form — with or without accessory spine originating from its lower margin or as a laterally narrowed form. The length and width of the foramen ovale were insignificantly higher in males than in females. The same results were found for the area of the right superior orbital fissure. The thickness of the frontal and occipital squamae influenced the thickness of the temporal squama. The analysed individuals had asymmetrical, oval, or almond-shape ovale foramina. Unlike the seldom visible laterally narrowed form of the superior orbital fissure, a wide form with or without accessory spine was the most commonly observed. The diameters of both superior orbital fissures and ovale foramina indicated the asymmetry of the neurocranium. (Folia Morphol 2011; 70, 4: 263–271)*

**Key words:** foramen ovale, superior orbital fissure, skull, middle cranial fossa

## INTRODUCTION

The middle cranial fossa is an important area of the skull, which contains the main part of the temporal lobes laterally and the pituitary gland centrally [3, 22]. Some other important anatomical structures such as selected dura mater venous sinuses, cranial nerves, and meninges are also there. Beside the anterior and posterior cranial fossae, the middle one is also connected with an orbit by the optic canal and superior orbital fissure, with a pterygopalatine fossa by the foramen rotundum, as well as with the base of the skull by the foramen ovale, spinosum, and lacerum. The greater and lesser petrosal hiatus/canal connects the structure with a facial canal and a tympanic cavity, respectively. Some other foramina — regarded as anatomical variances of sphenoid wings and on the level of surrounded synchondroses and sutures — were also revealed [31].

Knowledge about the localisation of the mentioned structures, their size, and anatomical variations is important for both physicians and anthropologists [9, 20, 22, 31]. The aim of the study was the retrospective morphological analysis of selected structures of the middle cranial fossa, i.e. foramen ovale and superior orbital fissure, in relation to the external head and cranial diameters in adult individuals from the Lublin Region (Poland). Both structures were selected since they are relatively big and easily visible in radiological examinations and their morphologies were not extensively studied before in a contemporary European population. Unlike most of the previous studies in which the cranial morphology was evaluated on historical and/or archaeological material [1, 8, 27, 28, 33, 37–40], the current study was performed radiologically using computed tomography images of skulls without any developmental abnormalities.

## MATERIAL AND METHODS

This study was conducted on the retrospective data from the First Department of Radiology and Nuclear Medicine, Medical University of Lublin. Records of 60 randomly selected Caucasian patients in the age group 20–30 years (30 males —  $24.66 \pm 3.37$  years, 30 females —  $24.76 \pm 2.72$  years) were examined. None of the patients had significant cranial or cerebral abnormalities.

All examinations were performed by means of LightSpeed Ultra CT 64-row VCT (GM Medical System). They were conducted with a standard clinical protocol in layers 5 and 2.5 mm above and below the upper Frankfort line, respectively. During post-processing, spatial imaging of soft tissues was per-

formed to estimate the length and width of the head. According to the guidelines for anthropological research [18, 22], the length of the head was assumed to be the distance between the glabella and opistocranium on the occipital squama (*g-op*). The width was measured between the two most remote points located on the right and the left side of the head (*eu-eu*). Furthermore, using volumetric option, spatial imaging of the skull was performed in order to measure the length (*g-op*) and width (*eu-eu*) of the skull.

After removing the calvaria the length and width of the ovale foramina were measured. Using the option of automatic field setting, the area of both superior orbital fissures was estimated. The area of the oval foramina (FoA) and the cross-sectional area of the skull (SA) were calculated using the following formula:  $FoA = \pi ab$ ;  $SA = \pi ab$ , where *a* and *b* indicate the half of the length and width of the oval, respectively. Moreover, the thickness of the frontal squama (1 cm above the centre of the right supraorbital margin), right temporal squama (1 cm above the upper pole of the external acoustic opening), and the occipital squama (1 cm above the right transverse sinus and 1 cm aside from the internal occipital protuberance) were measured. All measurements were performed using manufactory calibrated measurement window which guaranteed full repeatability of results.

The obtained data was presented using: arithmetical mean (M), 95% coefficient interval (CI), median (Me), minimal-maximal values (min–max), and standard deviation (SD). Depending on data distribution, checked by Kolmogorov-Smirnov test, differences were analysed by t-Student or Mann-Whitney U test. The correlations between examined parameters were checked by Spearman's rank. Nominal scale measures were analysed by Chi-square test with Fisher correction. A 0.05 level ( $p < 0.05$ ) of probability was used as the criterion of significance.

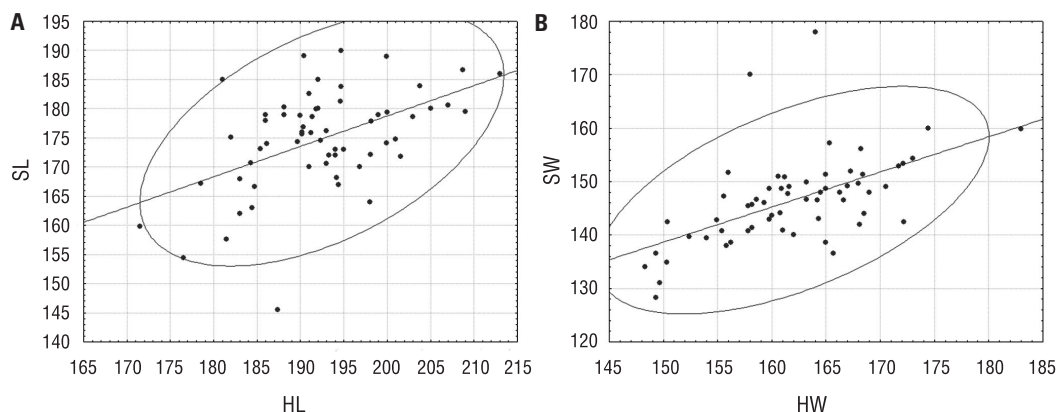
## RESULTS

In all analysed cases, well-developed cranial structures were found. Morphologically, they corresponded to the calendar age of the patients, a fact which was confirmed by the complete disappearance of the frontal suture as well as intra-occipital and sphenoccipital synchondroses. Sutures of the calvaria showed complete development without distinctive features of senile atrophy. Large, radiologically visible additional cranial bones were not found in any of the cases.

The length and the width of the head were significantly higher in males than in females (Table 1). Similar observations were made for external dimen-

**Table 1.** Diameters (mm) of head and skull in examined males (M) and females (F)

	Sex	M	-95 CI (%)	+95 CI (%)	Me	Min	Max	SD	P
Head length	M	196.423	193.560	199.286	194.650	183.000	213.000	7.667	0.001
	F	188.507	185.972	191.041	190.100	171.500	199.900	6.788	
Head width	M	166.223	164.109	168.338	165.500	154.900	183.000	5.663	0.0001
	F	157.723	155.601	159.846	158.100	148.300	169.000	5.685	
Cranial length	M	178.600	176.503	180.697	179.000	167.000	189.100	5.617	0.0004
	F	171.057	167.567	174.546	172.000	145.500	189.900	9.345	
Cranial width	M	149.547	146.615	152.479	148.850	136.600	178.000	7.852	0.0042
	F	143.517	140.602	146.432	143.250	128.300	170.100	7.807	
Frontal squama thickness	M	4.069	3.729	4.409	4.200	2.400	6.500	0.893	0.7813
	F	4.228	3.727	4.729	4.200	1.900	7.300	1.213	
Temporal squama thickness	M	3.277	2.912	3.641	3.150	1.700	5.600	0.975	0.3219
	F	3.520	3.139	3.901	3.300	1.900	7.300	1.020	
Occipital squama thickness	M	3.930	3.618	4.242	4.050	2.000	6.100	0.837	0.3292
	F	3.820	3.423	4.217	3.800	2.200	7.800	1.063	

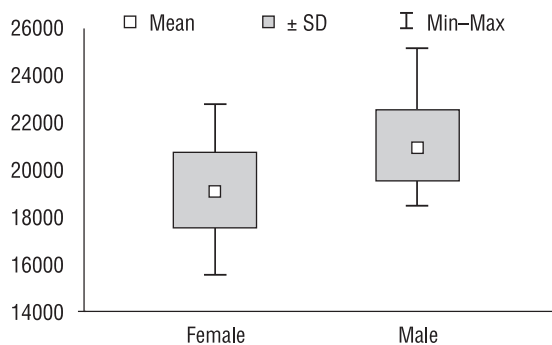


**Figure 1.** A. Skull length (SL;  $y = 74.5097 + 0.5212x$ ;  $R_s = 0.43$ ,  $p < 0.001$ ) in relation to head length (HL); B. Skull width (SW;  $y = 40.0689 + 0.6573x$ ;  $R_s = 0.61$ ,  $p < 0.001$ ) in relation to head width (HW). All the data is presented in mm.

sions of the skull. A positive, statistically significant correlation between the dimensions of the head and the skull in all examined patients was noted. Such correlation was found both for the length (Fig. 1A) and width (Fig. 1B). An insignificant difference in the cross-sectional area of the skull in relation to gender was revealed (Fig. 2).

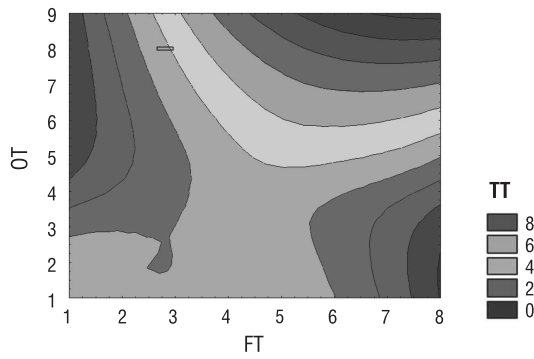
Insignificant thinning of the frontal and temporal squama was found in males in comparison to females (Table 1). A pooled analysis of all individuals provided evidence that the thickness of the frontal and occipital squama correlates with the thickness of the temporal squama (Fig. 3).

In the analysed material, the oval foramina were always present. Almond (Fig. 4A) and oval (Fig. 4B) shape were the most typical for the foramen. Less frequently, round or irregular (Fig. 4C) forms were



**Figure 2.** Cross-sectional area (mm<sup>2</sup>) of the skull on the level of glabella and opistocranium.

also observed. In one case, a significant decrease in the area of the foramen was found. However, more often a different degree of asymmetry be-

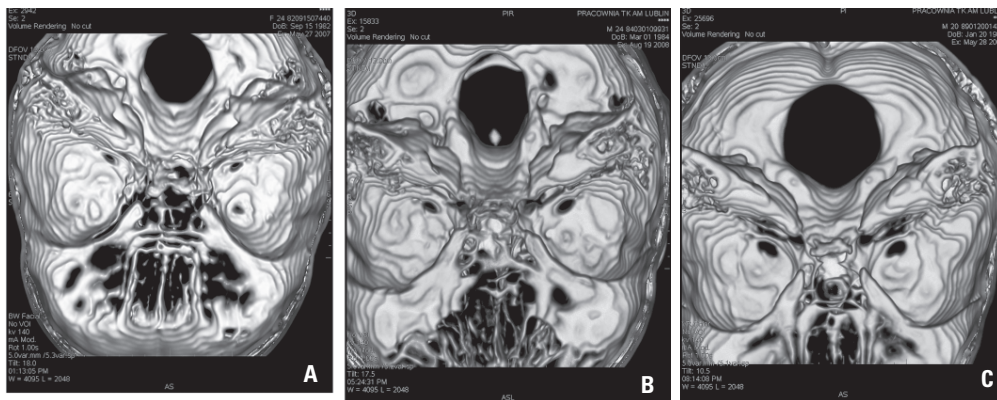


**Figure 3.** Thickness (mm) of the temporal squama (TT) in relation to the thickness of the occipital (OT) and frontal (FT) squama.

tween the right and the left side was observed (Fig. 4B, C). In two cases, uni- or bilateral small osseous spines were seen (Fig. 4C). Apart from that, no other additional ridges or any other bony elements which would divide the foramen into multiple structures were present. Moreover, a lack of direct or partial fusion of the foramen ovale and spinosum was observed.

The length and width of the foramen ovale was insignificantly higher in males than in females (Table 2). The lack of any considerable differences was also observed between the left and the right side (Fig. 5). Moreover, the area of both foramina was insignificantly higher in males (Fig. 6). Irrespective of gender, higher values of the parameter ( $p > 0.05$ ) were found on the left side. No correlation between the area of both oval foramina and cross-sectional area of the skull was observed (Fig. 7).

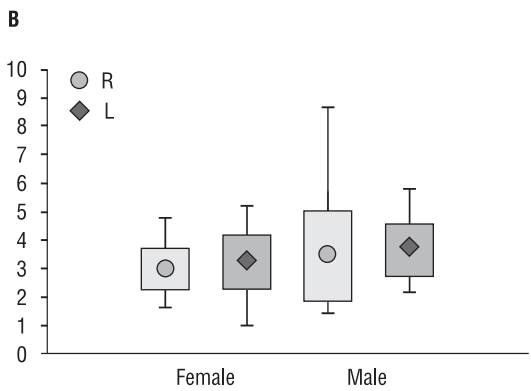
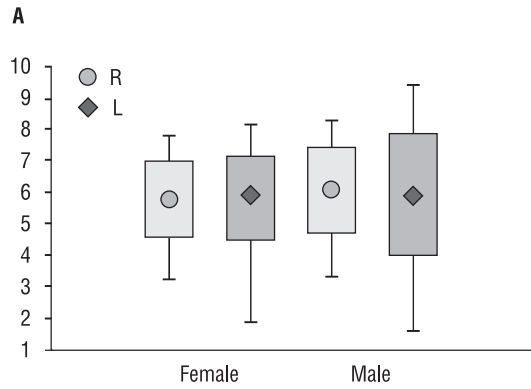
Superior orbital fissures were usually symmetrical with a vast morphological variety (Fig. 8). This concerned in particular the lateral part, which in some individuals was considerably narrowed (triangular type; Fig. 8B) and therefore made the area difficult to measure. In seven cases (4 male, 3 female), a symmetrical bilateral bony prominence — sticking out from the rim of the great sphenoid wing — was observed. It had the shape of widely pedunculated, smoothly rimmed spine which divided the fissure into medial and lateral parts (Fig. 8C, D). The height of the structure varied, but it never reached the upper margin of the fissure. Irrespective of the



**Figure 4.** Morphology of the foramen ovale in the pseudo-3-dimensional reconstruction of the skull. **A.** Asymmetrical, almond-shaped foramina; **B.** Asymmetrical, oval-shaped foramina; **C.** Asymmetrical, irregular foramina with accessory spine.

**Table 2.** Diameters (mm) of the right and left foramen ovale in examined males (M) and females (F)

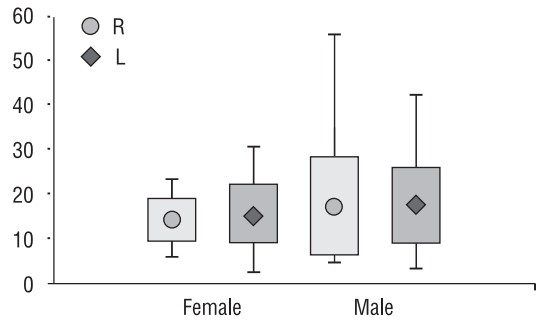
	Sex	M	-95 CI (%)	+95 CI (%)	Me	Min	Max	SD	P
Right — length	M	6.070	5.583	6.557	6.200	3.300	8.300	1.305	0.4035
	F	5.793	5.358	6.229	5.900	3.200	7.800	1.166	
Right — width	M	3.477	2.882	4.071	3.150	1.400	8.700	1.592	0.5298
	F	3.050	2.774	3.326	3.050	1.700	4.800	0.738	
Left — length	M	5.913	5.202	6.624	5.750	1.600	9.300	1.904	0.8073
	F	5.817	5.346	6.287	5.650	1.900	8.100	1.261	
Left — width	M	3.650	3.292	4.008	3.550	2.100	5.800	0.959	0.0555
	F	3.200	2.865	3.535	3.100	1.000	5.200	0.898	



**Figure 5.** The length (A) and width (B) of the right and left foramen ovale. Data presented in mm; middle point: mean, box:  $\pm$  SD, whisker: min-max.

height, all the observed spines were present only in wide fissures (round type) without the narrowing of the lateral part.

The area of the right orbital fissure was insignificantly higher in males than in females (Table 3). The reverse correlation was observed on the left side.



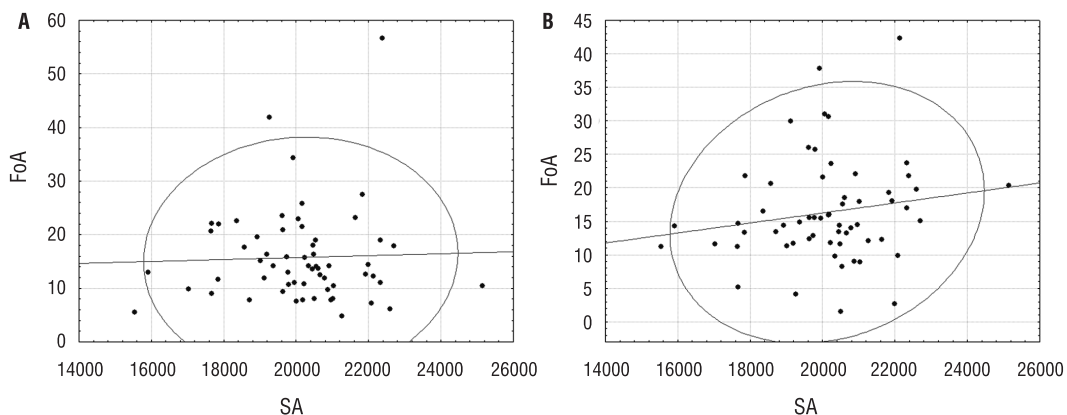
**Figure 6.** Area (mm<sup>2</sup>) of the right and left foramen ovale; middle point: mean, box:  $\pm$  SD, whisker: min-max.

The differences between the sides were also insignificant among the same gender (Fig. 9).

## DISCUSSION

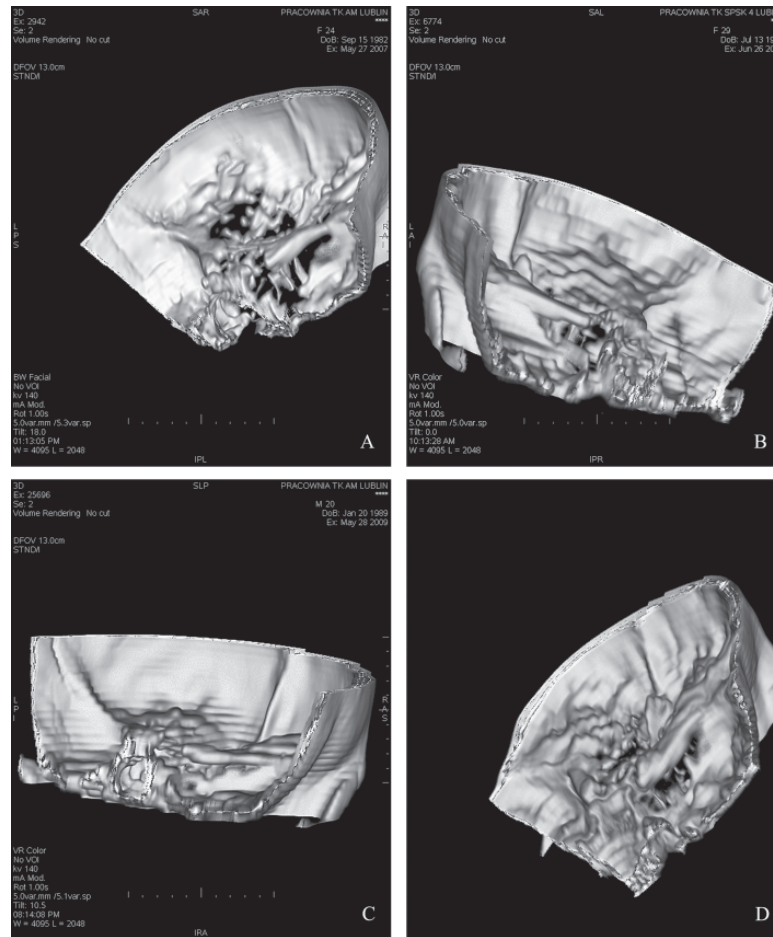
The study provides evidence for a logical correlation between the head and skull external dimensions. Furthermore, significant differences between male and female individuals were observed for external diameters of the neurocranium. Insignificant data was found for the thickness of analysed squamae, superior orbital fissures, and oval foramina.

The superior orbital fissure links the middle cranial fossa with the orbit. It is located laterally to the body of the sphenoid bone, and from the top and bottom is surrounded, respectively, by the greater and lesser sphenoid wing. It usually has an irregular, smoothly rimmed shape resembling a diagonally laid number eight [23, 31]. Its wider middle part is partly covered by the common tendinous ring of the external eye muscles. The lateral part is more narrowed [20, 22], which often made

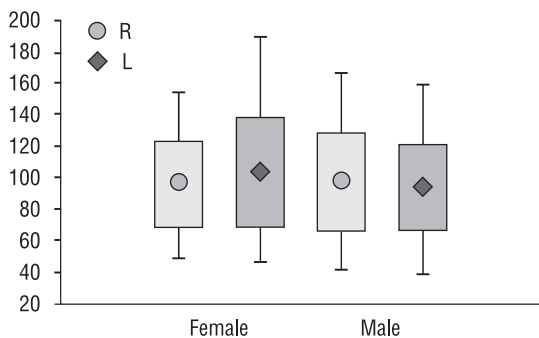


**Figure 7.** Area of the right (A.  $y = 12.1149 + 0.0002x$ ,  $R_s = -0.13$ ,  $p = 0.3337$ ) and left (B.  $y = 1.3047 + 0.0007x$ ;  $R_s = 0.15$ ,  $p = 0.2613$ ) foramen ovale (FoA) in relation to the cross-sectional area of the skull (SA). All the data is presented in mm<sup>2</sup>.





**Figure 8.** Morphology of the superior orbital fissure in the pseudo-3-dimensional skull reconstruction. Wide fissures — round type (A) and considerably narrowed — triangular type (B) without any accessory spine. Short (C) and high (D) accessory spine at the level of the fissure.



**Figure 9.** Area (mm<sup>2</sup>) of the right and left superior orbital fissures; middle point: mean, box:  $\pm$  SD, whisker: min–max.

difficult to measure its area. On the lateral circumference of the fissure, directly within the edge of the lesser sphenoid wing, there can be a small meningo-lacrimalis foramen, which contains a fine homonymous artery departing from the lacrimal artery, and, after entering the middle cranial fossa, it either unites with the middle meningeal artery or it independently vascularises the dura mater of the lateral part of the floor of the anterior cranial fossa [19, 26, 29]. Despite the detailed analysis of the examined material, the above foramen was not found in any skull. Moreover, there was a

**Table 3.** Area (mm<sup>2</sup>) of the superior orbital fissure in examined males (M) and females (F)

	Sex	M	-95 CI (%)	+95 CI (%)	Me	Min	Max	SD	P
Right	M	96.943	85.571	108.316	100.300	41.500	166.700	30.456	0.6789
	F	93.713	83.261	104.165	91.950	48.100	155.000	27.991	
Left	M	93.490	83.415	103.565	91.850	39.500	159.000	26.981	0.5742
	F	102.140	88.340	115.940	96.750	45.800	189.700	36.958	

lack of data on the area of superior orbital fissure in available literature.

The foramen ovale is located in the middle-posterior part of the greater sphenoid wing. Slightly to the back and to the side, there is a smaller foramen spinosum [20]. In isolated cases both foramina can unite forming more or less separated parts [13]. However, unilateral union of both structures was described by Ginsberg et al. [6] only in 2 out of 123 analysed skulls. In the examined group there was no case of union of both foramina. Another anatomical variance is a partially open foramen ovale which, through cartilage, is linked to the sphenopetrosal fissure. This type of variety is most frequent in the analysed region and was described by many authors [6, 21, 31] but not in the presently discussed population. Another variance is the occurrence of an innominate canal/foramen (Arnold's canal) or foramen petrosum located between the foramen ovale and foramen rotundum, which leads the lesser petrosal nerve. Occasionally, medially and anteriorly to the foramen ovale, another opening (foramen venosum [foramen of Vesalius]) could be visible. It contains the sphenoidal cardiac vein linking the cavernous sinus with the pterygoid plexus. The above-mentioned anatomical variety was confirmed in 17% of macerated skulls analysed by Reymond et al. [24]. A greater frequency of the foramen was recorded in Japanese studies [12], in which the structure was found in children's skulls (11/20 analysed, 55%) as well as in adults' (87/400, 21.75%). The foramen was observed more frequently in women (18/79, 22.78%) than in men (69/321, 21.5%). In 75 and 72 female and male skulls, respectively, the structure was bilateral. However, in a recent study [32] the foramen was present in 135 (33.75%) out of 400 examined skulls, while bilateral structures were confirmed only in 15.5% of cases. Higher incidence (60% and 80%, respectively) was reported on the basis of radiological analysis by Lanzieri et al. [16] and Ginsberg et al. [6]. The lack of foramina mentioned previously in the presently examined skulls may result from both the minor dimensions of the structures and the low incidence of the sphenoidal cardiac vein being present in individuals after puberty [24]. In available literature the presence of an additional foramen ovale located on the anterior and middle circumference of the proper structure was also described [1, 14, 24, 34]. In a single case a canal-like form was also reported [34]. Moreover, on the lower surface of the greater sphenoid wing, in the direct vicinity of the foramen ovale, a Civini's and Hyrtl's foramen can occasionally be seen (so called

meningo-orbital foramen), which was formed as a result of pathological ossification of the pterygospinous and pterygoalar ligament [38].

The size of the foramen ovale presented in this study is smaller than that described previously by Ray et al. [23]. The average length and width on the right side was, according to the authors,  $7.46 \pm 1.41$  and  $3.21 \pm 1.02$  mm, respectively, whereas on the left side it was  $7.01 \pm 1.41$  and  $3.29 \pm 0.85$  mm, respectively. The observed discrepancies may result from racial dissimilarities and the applied methods of measurement. The authors performed direct measurements on 35 macerated skulls of individuals from middle Nepal. In most cases they observed a typical oval outline of the foramen (22 on the right side — R, 21 on the left side — L). Less frequently an almond-shaped (11R, 13L), round (1R, 1L), or slit-like (1R) foramen was found. It is worth mentioning that bilaterally symmetrical foramen ovale were observed in only 15 cases, while bilateral almond-shaped foramen were seen in 7 cases. Unlike the currently discussed Polish population, in 24.2% of cases the occurrence of bony plates (4R, 5L), spines (1R, 2L), and marginal tubercles (1R, 2L) as well as spurs (1R, 1L) — which completely divided the foramen into two usually asymmetrical parts — were found. The infrequent occurrence of the above-mentioned structures was shown also in the Polish population [24]. Out of 100 skulls examined, the authors found 2–3 connecting interstices of the foramen ovale only in 4 cases.

Similar results of longitudinal dimension measurement of the foramen ovale (4.17–7.48 mm) were provided by Yanagi [40]. According to other authors, the length and width of the foramen range from 6.5 to 11.3 and 3.9 to 4.7 mm, respectively [2, 4, 17, 30]. The area of the foramen is also characterised by a considerable range of the values according to the above-mentioned authors (25.24–115.31 mm<sup>2</sup>), but the average values is around 28 mm<sup>2</sup> (total value for both foramina). This is slightly higher than in our study. Furthermore, Reymond et al. [24] estimated the area of the left foramen to be  $17.39 \pm 4.75$  and  $17.66 \pm 6.46$  mm<sup>2</sup> and the area of the right foramen to be  $19.43 \pm 5.59$  and  $20.92 \pm 5.56$  mm<sup>2</sup> in men (n = 49) and in women (n = 48), respectively. Similar data is presented by Teul et al. [37], who assessed the dimensions and morphology of foramina ovale and foramina spinosa on the basis of 102 male skulls from a medieval cemetery in Cedynia and on 85 contemporary skulls. However, the study was conducted with analogous radiograms which made it impossible to conduct the spatial assessment of the skele-

ton. The size of the foramen ovale in both groups was higher on the left side, which coincides with the findings obtained from women analysed in this study. In the case of men, converse data was collected concerning the length of the foramen, which was higher on the right side.

The data presented in this study on superior orbital fissure and foramina ovale indicate skull asymmetry. It confirms also the information obtained by above quoted authors [11, 23, 37]. According to present knowledge, this is the result of many factors that influence the human body in the pre- and postnatal period. The first group includes an asymmetrical foetal position in the uterine cavity and amniotic sac, which may result in changes within the muscle attachments. Appropriate development of the skull is also determined by the brain formation [3, 37]. The majority of anatomical brain abnormalities involve asymmetrical deformity of the cranial bones, and the degree of asymmetry is highest in the disorder of development of temporal bone, sphenoid bone, and mandible [7, 10, 15, 18, 37]. In the postnatal period, alimentary deficiencies as well as conditions and pathological states directly affecting bone mineralisation play a crucial role [3]. Important factors also include customs prevalent in a given population, which may significantly change the morphology of the skeleton. They include tying up and stiffening selected parts of the body, assuming an enforced position for a long time, and as for the skull, the practice of using a pillow or any other object which supports the head while sleeping is also important [10, 18, 25, 37]. It should be stressed that at the turn of skull age and geographical origin the character of the differences described above was changing. Among numerous studies published on the topic, the findings of Gawlikowska et al. [5] are worth mentioning. They assessed fluctuating asymmetry of 82 contemporary skulls and 77 medieval ones from a burial ground in Gródek upon Bug River (Poland). On the basis of radiogram analysis, it was demonstrated that contemporary skulls are characterised by high values of calvaria asymmetry and low values of facial skeleton asymmetry. An inverse proportion was found for the medieval skulls. These findings indicate increased impact of stress in ontogenesis and the decrease in compensation abilities in contemporary individuals.

The provided data point out that all analysed parameters were higher on the left in female which coincides with previous observations of other authors [8, 16, 18, 36, 40]. In men, greater area of superior orbital fissure and longer foramen ovale were observed on the right side. However, cross-

sectional dimension of the foramen was greater on the left side. Differences dependent on gender concerning morphology and dimensions of foramina of cranial base are given also by Yanagi [40], Ginsberg et al. [6], and Skvarilová [35, 36]. Schelling [30] demonstrated the presence of bigger foramen ovale on the left side in as many as 55% of cases, and equal dimensions only in 17.5%. In contrast, Raymond et al. [24] recorded both in men and women greater occurrence on the right side. It should be stressed that, similar to our study, the authors did not observe any significant differences between the left and the right side. It is probably secondary to the fact that only patients without any anatomical head abnormalities were selected for the final analysis. Brain and cranial injuries, in accordance with previously presented data, could considerably affected the obtained results.

## CONCLUSIONS

1. Thickness of the frontal and the occipital squamae influenced the thickness of the temporal squama.
2. Analysed individuals have asymmetrical, oval, or almond-shape ovale foramina.
3. The area of the foramen ovale does not correlate with the horizontal area of the skull (on the level of *g-op*).
4. Unlike the seldom visible, laterally narrowed form of the superior orbital fissure, a wide form with or without accessory spine was the most commonly observed.
5. The diameters of both superior orbital fissures and ovale foramina indicated asymmetry of the neurocranium.
6. Pseudo-3-dimensional radiological reconstruction gives a good view of the skull.
7. Radiological evaluation of the external head diameters is a good basis for anthropological analysis of the skull.

## REFERENCES

1. Abd Latiff A, Das S, Sulaiman IM, Hlaing KP, Suhaimi FH, Ghazalli H, Othman F (2009) The accessory foramen ovale of the skull: an osteological study. *Clin Ter*, 160: 291–293.
2. Berlis A, Putz R, Schumacher M (1992) Direct and CT measurements of canals and foramina of the skull base. *Br J Radiol*, 65: 653–661.
3. Burdan F (2005) Rozwój i wady wrodzone szkieletu. *Pol Merk Lek*, 9: 94–97.
4. Calcaterra TC, Cherney EF, Hanafee WF (1973) Normal variations in size and neoplastic changes of skull foramina. *Laryngoscope*, 83: 1385–1397.



5. Gawlikowska A, Szczurowski J, Czerwiński F, Miklaszewska D, Adamiec E, Dzieciołowska E (2007) The fluctuating asymmetry of medieval and modern human skulls. *HOMO*, 58: 159–72.
6. Ginsberg LE, Pruett SW, Chen MY, Elster AD (1994) Skull-base foramina of the middle cranial fossa: reassessment of normal variation with high-resolution CT. *Am J Neuroradiol*, 15: 283–291.
7. Good S, Edler R, Wertheim D, Greenhill D (2006) A computerized photographic assessment of the relationship between skeletal discrepancy and mandibular outline asymmetry. *Eur J Orthod*, 28: 97–102.
8. Gundara N, Zivanovic S (1968) Asymmetry in East African skulls. *Am J Phys Anthropol*, 28: 331–337.
9. Idowu OE, Balogun BO, Okoli CA (2009) Dimensions, septation, and pattern of pneumatization of the sphenoidal sinus. *Folia Morphol*, 68: 228–232.
10. Jain KK, Jain BK (1979) Asymmetry in the skull. *Acta Anat*, 104: 349–352.
11. Kazkayasi M, Ergin A, Ersoy M, Bengi O, Tekdemir I, Elhan A (2001) Certain anatomical relations and the precise morphometry of the infraorbital foramen: canal and groove: an anatomical and cephalometric study. *Laryngoscope*, 111: 609–614.
12. Kodama K, Inoue K, Nagashima M, Matsumura G, Watanabe S, Kodama G (1997) Studies on the foramen vesalius in the Japanese juvenile and adult skulls. *Hokkaido Igaku Zasshi*, 72: 667–674.
13. Krayenbühl N, Isolan GR, Al-Mefty O (2008) The foramen spinosum: a landmark in middle fossa surgery. *Neurosurg Rev*, 31: 397–402.
14. Krmpotić-Nemanić J, Vinter I, Jalsovec D (2001) Accessory foramen ovale. *Ann Anat*, 183: 293–295.
15. Kwon TG, Park HS, Ryoo HM, Lee SH (2006) A comparison of craniofacial morphology in patients with and without facial asymmetry: a three-dimensional analysis with computed tomography. *Int J Oral Maxillofac Surg*, 35: 43–48.
16. Lanzieri CF, Duchesneau PM, Rosenbloom SA, Smith AS, Rosenbaum AE (1988) The significance of asymmetry of the foramen of Vesalius. *Am J Neuroradiol*, 9: 1201–1204.
17. Lindblom K (1936) A roentgenographic study of the vascular channels of the skull. *Acta Radiol*, 30: 211–223.
18. Malinowski A, Strzałko J (1985) *Antropologia*. PWN, Warszawa.
19. Mysorekar VR, Nandedkar AN (1987) The groove in the lateral wall of the human orbit. *J Anat*, 151: 255–257.
20. Narkiewicz O, Dziewiątkowski J, Kowiański P, Wójcik S, Spodnik JH (2010) Głowa. In: Narkiewicz O, Moryś J ed. *Anatomia człowieka. Vol. IV*. Wydawnictwo Lekarskie PZWL, Warszawa, pp. 83–265.
21. Ossenberg NS (1976) Within and between race distances in population studies based on discrete traits of the human skull. *Am J Phys Anthropol*, 45: 701–715.
22. Piontek J (1999) *Biologia populacji pradziejowych*. Wydawnictwo Naukowe UAM, Poznań.
23. Ray B, Gupta N, Ghose S (2005) Anatomic variations of foramen ovale. *Kathmandu Univ Med J*, 3: 64–68.
24. Reymond J, Charuta A, Wysocki J (2005) The morphology and morphometry of the foramina of the greater wing of the human sphenoid bone. *Folia Morphol*, 64: 188–193.
25. Rossi M, Ribeiro E, Smith R (2003) Craniofacial asymmetry in development: an anatomical study. *Angle Orthod*, 73: 381–385.
26. Royle G (1973) A groove in the lateral wall of the orbit. *J Anat*, 115: 461–465.
27. Rusu MC (2010) Microanatomy of the neural scaffold of the pterygopalatine fossa in humans: trigeminovascular projections and trigeminal-autonomic plexuses. *Folia Morphol*, 69: 84–91.
28. Ryniewicz AM, Skrzat J, Ryniewicz A, Ryniewicz W, Walocha J (2010) Geometry of the articular facets of the lateral atlanto-axial joints in the case of occipitalization. *Folia Morphol*, 69: 147–153.
29. Santo Neto H, Penteado CV, de Carvalho VC (1984) Presence of a groove in the lateral wall of the human orbit. *J Anat*, 138: 631–633.
30. Schelling F (1978) The emissaries of the human skull. *Anat Anz*, 143: 340–382.
31. Scheuer L, Black S (2000) *Developmental juvenile osteology*. Academic Press, San Diego.
32. Shinohara AL, de Souza Melo CG, Silveira EM, Lauris JR, Andreo JC, de Castro Rodrigues A (2010) Incidence, morphology and morphometry of the foramen of Vesalius: complementary study for a safer planning and execution of the trigeminal rhizotomy technique. *Surg Radiol Anat*, 32: 159–164.
33. Skrzat J, Walocha J, Środek R, Niżankowska A (2006) An atypical position of the foramen ovale. *Folia Morphol*, 65: 369–399.
34. Skrzat J, Mróz I, Jaworek JK, Walocha J (2010) A case of occipitalization in the human skull. *Folia Morphol*, 69: 134–137.
35. Skvarilová B (1993) Facial asymmetry: type, extent and range of normal values. *Acta Chir Plast*, 35: 173–180.
36. Skvarilová B (1994) Facial asymmetry: an X-ray study. *Acta Chir Plast*, 36: 89–91.
37. Teul I, Czerwiński F, Gawlikowska A, Konstany-Kurkiewicz V, Sławiński G (2002) Asymmetry of the ovale and spinous foramina in mediaeval and contemporary skulls in radiological examinations. *Folia Morphol*, 61: 147–152.
38. Tubbs RS, May WR Jr, Apaydin N, Shoja MM, Shokouhi G, Loukas M, Cohen-Gadol AA (2009) Ossification of ligaments near the foramen ovale: an anatomic study with potential clinical significance regarding transcutaneous approaches to the skull base. *Neurosurgery*, 65 (6 suppl): 60–64.
39. Wysocki J, Reymond J, Skarzyński H, Wróbel B (2006) The size of selected human skull foramina in relation to skull capacity. *Folia Morphol*, 65: 301–308.
40. Yanagi S (1987) Developmental studies on the foramen rotundum, foramen ovale and foramen spinosum of the human sphenoid bone. *Hokkaido Igaku Zasshi*, 62: 485–496.